

ORTHOPEDIC FOUNDATION FOR ANIMALS, INC.



FIRST CLASS LILAC TITAN
registered name

FRENCH BULLDOG
breed

985112001135953 DNA:V797698
tattoo/microchip/DNA profile

1926384
application number

11/13/2017
date of report

RESULTS:

The results of the examination submitted to OFA indicate that no evidence of patellar luxation was recognized.

NP39210203
registration no.

M
sex

1/24/2015
date of birth

32
age at evaluation in months

FBU-PA2447/32M/P-VPI
O.F.A. NUMBER

*This number issued with the right to correct or
revoke by the Orthopedic Foundation for Animals.*



A Not-For-Profit Organization

owner

LARRY HERSCHBERGER
1673 COUNTY RD 2000 N
ARTHUR, IL 61911

NORMAL - PRACTITIONER

G.G. KELLER, D.V.M., M.S., DACVR
CHIEF OF VETERINARY SERVICES

www.offa.org

ORTHOPEDIC FOUNDATION FOR ANIMALS, INC.

FIRST CLASS LILAC TITAN

registered name

FRENCH BULLDOG

breed

985112001135953 DNA:V797698

tattoo/microchip/DNA profile

1926384

application number

11/13/2017

date of report

RESULTS:

The results of the examination submitted to OFA indicate that no evidence of congenital cardiac disease was recognized.

NP39210203

registration no.

M

sex

1/24/2015

date of birth


32

age at evaluation in months

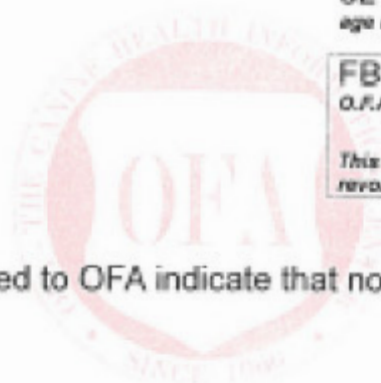
FBU-CA2415/32M/P-VPI

O.F.A. NUMBER

*This number issued with the right to correct or
revoke by the Orthopedic Foundation for Animals.*



A Not-For-Profit Organization



NORMAL - PRACTITIONER

G.G. Keller, D.V.M.

G.G.KELLER, D.V.M., M.S., DACVR
CHIEF OF VETERINARY SERVICES

OWNER

LARRY HERSCHBERGER
1673 COUNTY RD 2000 N
ARTHUR, IL 61911

www.offa.org

ORTHOPEDIC FOUNDATION FOR ANIMALS, INC.



FIRST CLASS LILAC TITAN
registered name

NP39210203
registration no.

FRENCH BULLDOG
breed

M
sex

1/24/2015
date of birth

985112001135953 DNA:V797698
tattoo/microchip/DNA profile

32
age at evaluation in months



A Not-For-Profit Organization

1926384
application number

FBU-1209F32M-VPI
O.F.A. NUMBER

11/14/2017
date of report

This number issued with the right to correct or revoke by the Orthopedic Foundation for Animals.

RESULTS:

Based upon the radiograph submitted, the consensus was that no evidence of hip dysplasia was recognized. The hip joint conformation was evaluated as:

FAIR

owner

LARRY HERSCHBERGER
1673 COUNTY RD 2000 N
ARTHUR, IL 61911

G.G.KELLER, D.V.M., M.S., DACVR
CHIEF OF VETERINARY SERVICES

www.offa.org